

MELDONIUM AS A CORRECTOR OF THE MORPHOFUNCTIONAL STATE OF THE HEART IN EXPERIMENTAL HYPOOSMOLAR OVERHYDRATION

Yarmolenko O., Sikora V., Bumeister V., Prykhodko O., Demikhova N.

Sumy State University, Ukraine

ABSTRACT

Last years a large number of clinical reports about water intoxication with detailed description of its symptoms. Undoubtedly, water intoxication leads to remodeling of the heart. However, the features of structural and functional changes of the heart are not fully understood. Prolonged hypoosmolar overhydration causes a volume overload necessitating cardioprotectors together with a complex of measures aimed at stabilizing the water and electrolyte balance. Our research is aimed to study the characteristics of the heart restructuring, changes of its chemical composition at severe hypoosmolar overhydration and attempt to correct the identified changes with derivative meldonium.

The experiment involved 36 white laboratory rats. We simulated severe overhydration during 25 days by the introduction of 10 ml distilled water three times a day and synthetic analogue of antidiuretic hormone "Minirin" (Ferring) 2 times a day at a dose 0.01 mg without cardioprotector (first experimental series) and with the parallel introduction of cardioprotector (second experimental series). To study the morphological and functional changes of the heart, we analyzed organometric, light microscopic, histomorphometric and spectrophotometric data.

The investigation showed that the meldonium slows the increasing of right ventricular weight and dilatation of its cavity, reduces the effects of cardiomyocytes ischemic damage, stabilizes the ratio of myocardial structural components, minimizes changes in the heart chemical composition.

Key words: overhydration, heart remodeling, cardiomyocyte, cardioprotector

INTRODUCTION

The water environment is an absolute component of homeostasis. Intake of adequate water is necessary for a full life. The physiological aspects of violations of water-electrolyte balance are fundamentally studied today. Experimental studies on animal models were devoted to morphological and functional changes of internal organs and the skeletal system during dehydration [Tvorko V., 2002; Polyakova V., Tkach G., 2006] and overhydration [Tkach G., 2012; Pogorielov M., 2008; Bolotna I., 2010; Korniykova I., 2012]. Recently the number of pathological States caused by the positive water balance of the organism increases, as evidenced by a large number of clinical messages. Symptoms of "water intoxication" are described among athletes [M. Martínez, 2010], psychiatric patients [D. Zilles et al., 2010; M. Funayama, T. Hisamatsu, A. Koreki, 2011], people who were forced to drink plenty of fluids to collect urine [M. Tilley, C. Cotant, 2011]

and to pass the ultrasound screening [Yalcin-Cakmakli G. et al, 2010]. When kidney failure even a small amount of water coming through the tube to lavement the gaster, leads to water intoxication [Sa D., Chen H., 2008]. Hypoosmolar overhydration may be caused by increased secretion of antidiuretic hormone (vasopressin). A significant number of lung tumors produce vasopressin themselves [Ganong V., 2002]. Secretion of antidiuretic hormone increases when taking certain medicines (barbiturates, morphine, glucocorticoids, potassium chloride, anesthetics), during stress, when carrying out an artificial lung ventilation with positive pressure. Hyperhydration accompanies acute and chronic renal failure [Alcázar Arroyo R., 2008]. The risk of death from cardiovascular disease among patients, that have peritoneal dialysis and hemodialysis, significantly increases due to the increasing amount of fluid in the body [FanS., Sayed R., Davenport, A., 2012; Wizemann V. et al, 2010]. Undoubtedly, a positive water balance affects the heart functioning and causes structural and functional changes in it. However, only a small amount of publications is devoted to the study of this problem [Du Y., 2010].

***Corresponding author:**

Email: nadezhda-sumy@mail.ru

Therefore the aim of our work was to determine morphological and functional changes in the hearts of laboratory animals under the influence of severe hyposmolar overhydration and the possibility of correction of the revealed violations with the help of cardioprotector.

MATERIALS AND METHODS

Fundamentally, the study was conducted on the "Center of Morphological Research", Sumy State University (Ukraine). The experiment involved 36 white laboratory rats 8 months aged, kept in the vivarium. All experiments were conducted accordingly to "European Convention of the Protection of Vertebrate Animals used for Experimental and other Scientific Purposes" (Strasbourg, 1986) and approved by the Commission on Biomedical Ethics of Medical Institute (report No 9/2 on 19.09.2013). The animals were divided into 3 series - 2 experimental and 1 control. Each series included 12 rats. Animals of the first experimental series were modeling severe hyposmolar overhydration by introduction of 10 ml distilled water three times a day through a tube. Animals were fed boiled unsalted food, and, to prevent physiological maintain of water homeostasis, they were injected a synthetic analogue of antidiuretic hormone "Minirin" (Ferring) with drinking water 2 times a day at a dose 0.01 mg. The simulation of severe overhydration lasted 25 days. To control the degree of osmolarity violation "decrement of osmolarity" we determined by the Dorvant formula: $\text{osmolality of blood plasma (mOsm / 1 kg water)} = 1,86 \cdot \text{Na (mol/l)} + \text{glucose (mol/l)} + \text{urea (mol/l)} + 9$. Criterion of hyposmolar syndrome was osmolality of plasma below 280 mOsm/kg and concentration of sodium less than 135 mmol/l. Animals were taken out of the experiment by the introduction ketamine at a dose of 70 mg / kg next day after achieving them the severe overhydration.

Rats of the second experimental series were also simulating severe hyposmolar overhydration and there was held an effort to correct morphological and functional changes of the myocardium using drug Vasopro"(pharmaceutical company "Farmak", Ukraine), which was injected intraperitoneally at a dose of 50 mg/kg once a day during the experiment. The active substance of the drug "Vasopro" is Meldonium. Its action is aimed at reducing the concentration of carnitine, which causes restriction of transport of activated forms of fatty acids into cells. The drug has antihypoxic, antiarrhythmic, antithrombotic effects, it can

expand arteriolae and improve contractile function of the myocardium [Dzerve V., Kalvinsh I., 2013].

The control animals were injected the "Mynyrin"(Ferring) twice a day at a dose of 0.01 mg, considering the potential effects of vasopressin on the cardiovascular system. Animals received normal drinking water and food within the daily physiological needs and were taken out of the experiment in parallel with experimental animals.

For the study of features of changing of the myocardium under the influence of overhydration we used the following research methods:

1. Organometric method. We separately weighed the left and right ventricles, interventricular septum, and atria by W. Muller with modification of R. M. Fulton et al., G. I. Illjina, measured the area of endocardial surfaces of both ventricles [Avtandilov G., 2002]. We calculated the following missameric indicators: the net weight of the heart (NWH) – the mass of the myocardium without valves, great blood vessels, subepicardial adipose tissue; the absolute weight of the left (WLV) and right (WRV) ventricles, proportional to their mass part of the interventricular septum, ventricular index (WI) is the ratio of MRV to MLV; the weight of both atria (MA). Using indirect planimetry we calculated the area of the endocardial surface of the left (ASLV) and right (ASRV) ventricles; planimetric index (PI) – the ratio of ASLV to ASRV.
2. Histological examination of the ventricular myocardium. The pieces of the ventricular myocardium were placed in 10% neutral formalin for a day, then were dehydrated in ethyl alcohol of increasing concentration and embedded in paraffin. Transverse and longitudinal histological sections with a thickness of 10 to 15 μm were stained with hematoxylin-eosin and HOPF-method [J. Lie, 1971] and were studied using a light microscope "OLIMPUS".
3. Histomorphometry. We measured the diameter of cardiomyocytes (DCMC) of the ventricles and their nuclei, using the computer program "Video Size 5.0"; the relative amount of cardiomyocytes (RACMC), connective tissue (RACT), vessels (RAV) in the left and right ventricles by the method of point counting [Avtandilov G., 2002], stromal-parenchymal ratio in the ventricles by the formula $(\text{RACT} + \text{RAV}) / \text{RACMC}$.

- Analysis of the chemical composition of the heart. We weighed hearts up to 0.001 g, placed them to a thermostat at a temperature of 105°C and dried to constant weight. By the difference of the wet and dry mass of the sample we determined the water content in the heart. The dried samples were incinerated in a muffle furnace at a temperature of 450°C to remove the organic matrix. The residue was dissolved in a mixture of salt (2 ml) and nitrogen (1 ml) acids and the solution volume was brought to 10 ml with bidistilled water. By flame atomization we determined the calcium content (wavelength - 422,7 nm), magnesium (wavelength - 285,2 nm), zinc (wavelength - RUB 213.9 nm), iron (wavelength - to 248.3 nm), using spectrophotometer C115-M1. Content of sodium (wavelength - 589,0 nm) and potassium (wavelength - 766,5 nm) was determined in the mode emission in a flame [Pogorelov M. et al., 2010]. To visualize the results of the study, the content of the studied elements is given in µg/g of wet tissue. Measurements and calculations were performed using the program AAS-SPECTR.
- A statistical method. Obtained digital data were processed on a personal computer using the software "GraphPad" [http://graphpad.com]. Reliable probability of error is taken less than or equal to 5% ($p \leq 0.05$).

RESULTS

The organometric data indicate a significant increasing of NWH in both experimental groups upon reaching severe overhydration by animals. However, separate weighing of the heart chambers shows more rapid increasing of mass and square of endocardial surface of the right ventricle in animals that were not

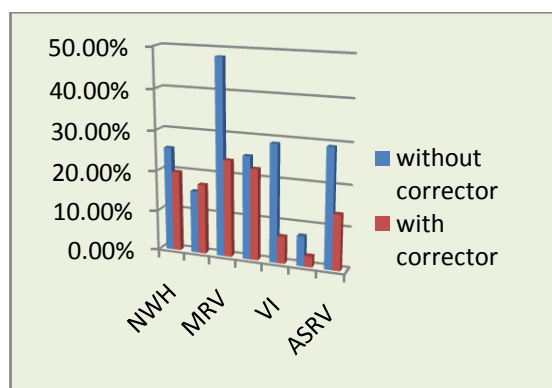


Fig. 1. The percentage of organometric heart indices of rats in two experimental series in comparison with the control.

injected "Vasopro" as a corrector. This is confirmed by the increasing of the WI on 28.89% ($p=0.0050$) and decreasing of PI on 16.93% ($p < 0.0001$) in comparison with the control series. The introduction of the corrector does not change the value of ventricular and planimetric index significantly (Fig.1).

Light microscopy of myocardium of rats, that have not received the corrector determines the homogenization of the muscle fibers and compression of the stroma as a result of swelling

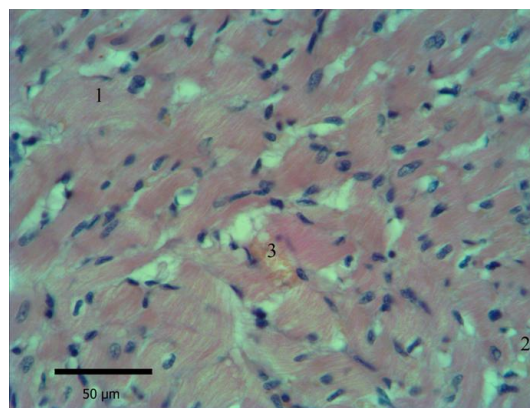


Fig. 2. The myocardium of the left ventricle of first experimental series rat. Staining with hematoxylin-eosin. Sell edema (1), hydropic dystrophy of CMC (2), capillary hyperemia (3), sections of CMC contractural damage (4).

of CMC. Transverse striations of myofibrils is expressed unevenly: sometimes reinforced, sometimes sites are identified cytolysis. The muscle fibers are disoriented, with lots of contractural damage. The nuclei of CMC are polymorphic, with indistinct contours and their

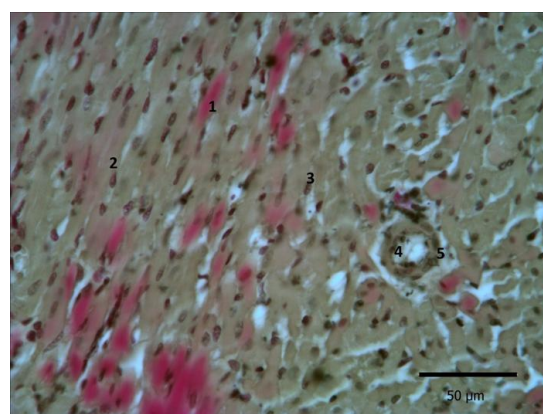


Fig. 3. The myocardium of the left ventricle of the rat of the first experimental series. Coloring GOFP method. Oc.X20, Ob.g.X40. Cytoplasm fuchsinophilia (1), intracellular edema (2), the regional location of the CMC nuclei(3), empty of vessels(4), perivascular edema (5).

peripheral position, the individual cells do not have nuclei. Areas of enlightenment of cytoplasm (cytolysis) and vacuoles, filled with fluid (hydropic degeneration), are visible in the perinuclear zone (Fig.2). In preparations stained HOFP-method fuchsinophilia plots are defined, indicating ischemic damage in CMC (Fig.3).

With the introduction of "Vazopro" in preparations of myocardium we observed isolated areas of fuchsinophilia, CMC nuclei are polymorphic with peripheral position (Figure 4).

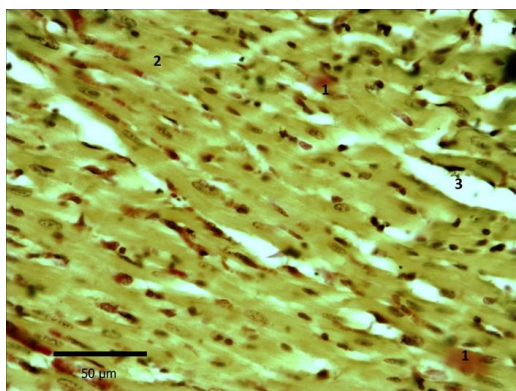


Fig. 4. The left ventricular myocardium of rat receiving the drug "Vazopro." Staining GOFP method. Ob.g. x40, oc.x20. Areas of fuchsinophilia (1), intracellular edema (2), stromal edema (3).

Myocardial histomorphometry in animals not treated with corrector determines more significant changes in comparison with the second experimental series (Figure 5). Thus DCMLV

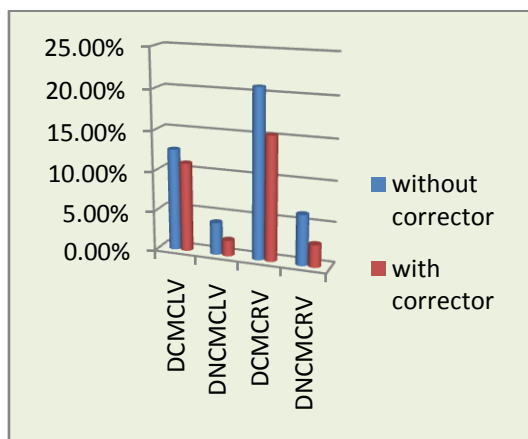


Figure 5. Percentages ratio of the rats hearts morphometric parameters of two experimental series in comparison with control.

increases by 12.61% ($p < 0.0001$) in comparison with the control, DNCMLV - to 4.01% ($p = 0.0348$), DCMRV to 16.88% ($p < 0.0001$) more control and

DNCMV - on 6.27% ($p = 0.0069$). Also change the relative morphometric parameters (Figure 6):

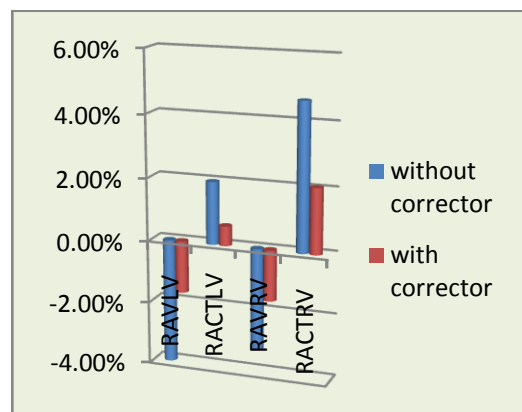


Fig. 6. Percentage ratio of the rats hearts morphometric parameters of two experimental series in comparison with control.

RAVLV reduces by 3.97% ($p = 0.0007$), and RAVRV - on 3.24% ($p = 0.0055$); RACTLV increases by 1.98% ($p = 0.0232$), and RACTRV - to 4.65% ($p = 0.0009$). The relative amount of CMC is not significantly changed. Also stromal-parenchymal relationship remains stable that indicates the presence of both stromal and cellular edema. Among rats receiving the drug "Vazopro" also observed a significant increase in the diameter of the CMC: DCMCLV increases by 11.03% ($p < 0.0001$), DCMCRV - at 15.36% ($p < 0.0001$). However, the rest of histomorphometric parameters vary insignificantly.

At severe hypoosmolar overhydration water content in the heart is on 15.75% ($p = 0.0027$) more than the reference value. When introducing

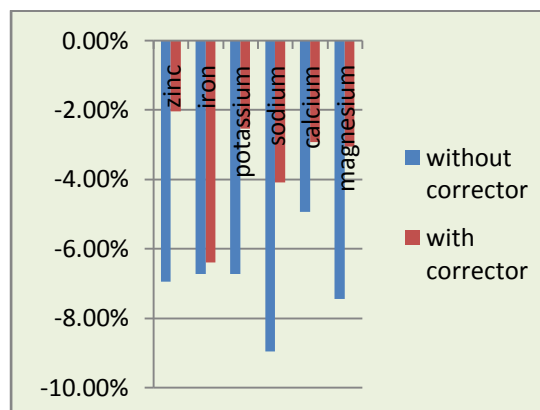


Fig. 7. The percentage ratio of the rats hearts chemical composition of two experimental series in comparison with control.

the corrector, hydration rate of the heart is slightly lower and this index is higher than the control on the 12.39% ($p = 0.0085$). In the first experimental group we observe reduction of all test elements: sodium - on the 8.97% ($p = 0.0009$), potassium - on

the 6.37% ($p = 0.0010$), magnesium - on the 7.45% ($p = 0.0401$), zinc - on the 6.95% ($p = 0.0343$), iron - on the 6.73% ($p = 0.0239$), and calcium - on the 6.52% ($p = 0.0424$). At the same time, in the second experimental group the sodium and the iron contents decrease on the 4.09% ($p = 0.0202$) and 6.41% ($p = 0.0450$) respectively (Fig.7).

DISCUSSION

We found that the derivative of meldonium "Vazopro" ("Farmak") increases the stability of the myocardium to volume overload, caused by water intoxicating, at all levels of structural organization. At the organ level remodeling of the heart of rats treated with "Vazopro" is proportional and is characterized by a significant slowdown in growth of the weight of the right ventricle, as well as a decrease of the rate of dilatation of its cavity. At the tissue level we observed decrease of ischemic damage of cardiomyocytes, the stabilization of the ratio of the myocardial structural components, we revealed signs of cardiac tissue hypertrophy (increased cross-striations of myofibrils, boundary location cores CMC), which is considered as an adaptive response of the myocardium to volume overload. Also selected corrector minimizes changes in the chemical composition of the hearts of laboratory animals, which has a positive effect on the functional state of the organ.

CONCLUSIONS

Thus, in case of violation of water - electrolyte balance, together with etiotropic therapy it is useful to introduce the cardioprotector Meldonium in order to mitigate the negative impact of volume overload on the myocardium.

REFERENCES

1. Zilles D, Hasan A, Gruber O., Aust NZ et al. Acute polydipsia and water intoxication in first episode schizophrenia. *J Psychiatry*. 2010; 44(5): 489.
2. Alcázar Arroyo R. Electrolyte and acid-base balance disorders in advanced chronic kidney disease. *Nefrologia*. 2008; 28: 87-93.
3. Avtandilov GG Fundamentals of quantitative pathological anatomy. M.: Medicine, 2002: 240 p.
4. Bolotna IV Structural transformations in the liver of animals due hyperhydrate violations of water-salt metabolism (experimental anatomical study): Abstract thesis for the sciences degree candidate of med.sciences in spec. 14.03.01 normal anatomy. - Kharkov, 2010: 19 p.
5. Dzerve VY, Kalvinsh IYa Mildronat in cardiology. A review of research. Riga, 2013: 76 p.
6. Fan S, Sayed RH, Davenport A Extracellular volume expansion in peritoneal dialysis patients. *The International Journal of artificial organs*. 2012; 35(5): 338-345.
7. Funayama M, Hisamatsu T, Koreki A Central pontine demyelination following water intoxication in schizophrenia. *Schizophr Res*. 2011; 125(2-3): 300-301.
8. Ganong WF Human Physiology. Lviv, 2002. - P.669-678.
9. Yalcin-Cakmakli G, Karli Oguz K, Shorbagi A. et al. Hyponatremic encephalopathy after excessive water ingestion prior to pelvic ultrasound: neuroimaging findings. *Intern Med*. 2010; 49 (16): 1807-1811.
10. Korniykova IP Morphological and functional transformation of the pituitary gland due hyperhydrate violations of water-salt metabolism: Abstract thesis for the sciences degree candidate of med. sciences in spec. 14.03.01 normal anatomy. - Lugansk, 2012: 19 p.
11. Lie JT, Holley KF, Kampa WR New histochemical method for morphologic diagnosis of early stages of myocardial ischemia *Mayo Clin Proc*. 1971; 46 (5): 319-327.
12. Martínez MJ Hyponatremia: classification and differential diagnosis *Endocrinol Nutr*. 2010; 57(2): 2-9.
13. Pogorelov MV, Bumeyster VI, Weaver GF, Bonchev SD et al. Macro- and microelements (exchange, pathology and methods of calculation): monograph. - Sumy Univ SSU, 2010. - 147 p.
14. Pogorelov MV Reparative osteogenesis of tibia in adult rats under mild hypoosmolar overhydration *Morphology*. 2008; II (4): 31-36.
15. Polyakova VI, Tkach GF Microstructural changes in the long bones regenerate under dehydration violations of WEB *Bulletin of problems in biology and medicine*. 2006; 2: 277-378.

16. Sa DD, Chen HH The role of natriuretic peptides in heart failure *Curr. Cardiol. Rep.* 2008; 10(3): 182-189.
17. Du Y, Plante E, Janicki JS, Brower GL Temporal valuation of cardiac myocyte hypertrophy and hyperplasia in male rats secondary to chronic volume overload *The American Journal of Pathology* . 2010; 177(3): 1155–1163.
18. Wizemann V, Wabel P, Chamney P et al. The mortality risk of overhydration in haemodialysis patients *Nephrol. Dial. Transplant.* 2009; 24 (5): 1574-1579.
19. Tilley MA, Cotant CL Acute water intoxication during military urine drug screening *Mil Med.* 2011; 176 (4): 451-453.
20. Tkach GF Adaptive-readaptive changes of bones in a hypohydrate violations of water-salt metabolism of the body: abstract dis. Dr. med. sciences: 14.03.01, normal anatomy. S.I.Georgievsky Crimea. State. Med. Univ. - Sympherop. [BV], 2012. – 32p.
21. Tvorko VM Morphological and functional features of myocardial adaptation to the general dehydration: for the sciences degree candidate of med. sciences in spec. 14.03.01 normal anatomy. - Ternopil, 2002. - 19 p.
22. Horn MM, Heytts UI, Swearingen PL et al. Water-electrolyte and acid-base balance: fold. Guide: per.s Eng. Ed. VJ Legeza. - M .: Binom; S-Petersburg.: Nevsky Dialekt, 1999. - 319 p.